

## Anorectal Malformation In A Major Pediatric Surgical Center- Diagnosis And Management

<sup>1</sup>DR VINAYAKUMAR SHELKE, <sup>2</sup>DR PUSHPENDRA SINGH KANWAR, <sup>3</sup>DR. SANDEEP AHIRWAR, <sup>4</sup>DR. ATUL KUMAR KHARE, <sup>4\*</sup>DR. AMIT KUMAR SINGH,  
MCH RESIDENT, DEPT OF PEDIATRIC SURGERY, VMMC AND SAFDARJUNG HOSPITAL, NEW DELHI, 110029  
MD RADIODIAGNOSIS, SENIOR RESIDENT NSCB JABALPUR  
RESIDENT IN DEPARTMENT OF PSYCHIATRY, MGM MEDICAL COLLEGE INDORE  
MCH RESIDENT, DEPARTMENT OF PEDIATRICS SURGERY, SMS MEDICAL COLLEGE JAIPUR  
EX. SENIOR RESIDENT, DEPARTMENT OF PAEDIATRICS, ALL INDIA INSTITUTE OF MEDICAL SCIENCES BHOPAL (M.P.)

### Abstract

**Background:** Anorectal malformation remains a common defect in pediatric surgical practice. There has been worldwide evolution in the management of this condition. Anorectal malformation is a common cause of intestinal obstruction in children. Anorectal malformation is a common congenital defect and its management has evolved over the years. Most of the patients presented as newborns to the emergency department. This is because anorectal malformation commonly presents with intestinal obstruction which is an emergency, patients frequently presented late with marked abdominal distension.

**Aims and objectives-** This is a retrospective and prospective review of medical records, operation registers and operation notes of patients managed for anorectal malformation of pediatrics surgery from June 2021 to June 2023 at major tertiary health care centre in India. The main aim of this study is “anorectal malformation in a major pediatric surgical center- diagnosis and management”.

**Materials and Methods:** A retrospective and prospective analysis of 590 patients with anorectal malformations managed from June 2021 to June 2023 was carried out. Demographic data, type of anomaly, mode of presentation, evaluation, treatment and outcome of treatment were obtained. Total 590 patients' data recorded. Data obtained were analysed using SPSS version 11.0. The  $\chi^2$  test was used to test for level of statistical significance. Level of statistical significance was set at 0.05.

**Results:** from this study we found that- There were a total 590 patients (376 boys and 214 girls). The median age at first surgery was 8 days (range 1 day–9 years). There were 358 emergency operations in and 232 elective operations were done. The main investigations for evaluation were a lateral cross table X-ray, abdominal ultrasonography, sacral X-ray, echocardiography and a distal cologram. Total 330 patients requiring colostomy had a transverse loop colostomy. 14 patients with recto-vestibular fistula were given a colostomy before the definitive surgery, while 28 patients with recto-vestibular fistula were managed without a colostomy. The definitive surgery done in 70 [30.14%] were cutback anoplasty, sacro-abdomino-perineal pull through 12 [5.17%], posterior sagittal ano-rectoplasty [PSARP] 104 [44.8%], anal dilatation 34 (14.6%), cruciate incision 8 (3.4%) and posterior sagittal ano-recto-vagino-urethroplasty (PSARVUP) 4 (1.72%) were done. Early complications were colostomy related. The early complication rate was 14 % (46 of 330). Most common complications are bowel evisceration 30.4%, surgical site infection 26%, stoma necrosis 13%, stoma stenosis 13% and stoma retraction 8.69% were found. Late complications following definitive treatment were: faecal incontinence 5 (4.3%), anal stenosis 70 (60.34%), rectal retraction 18 (15.5%), mucosal prolapse 20 (17.24%) and faecal soilage 3 (2.58%). Cause of death were 18 [ 3%] in which main causes are- anaesthetic deaths 2 (11.1%), overwhelming sepsis 4 (22.2%), dys-electrolytaemia 4 (22.2%) and nonspecific 8 (44.4%).

**Conclusion:** There have been significant changes in the management of anorectal malformations in this center, resulting in improved outcomes. This has been due to better understanding of the pathological condition and refinements in the surgical treatment.

**Keywords:** Anorectal malformation, recto-vestibular fistula, colostomy

## Introduction

Anorectal malformation remains a common defect in pediatric surgical practice. There has been worldwide evolution in the management of this condition.

Anorectal malformation is a common cause of intestinal obstruction in children. The incidence is 1:4000–5000 live births worldwide, but this could be more.[1]

The classification and management of this condition has evolved over the years. [2-6] Initially, these patients were allowed to die without treatment.[2] Now, all patients with this condition can be appropriately treated. The surgical evolution of the treatment for anorectal malformation can be seen in procedures ranging from Stephen, Rehbein, Romualdi, Kiesewetter to Pena.[7]

The changing trends have been geared towards improving the outcome of patients managed with this condition. The most common cause of morbidity following the management of this condition is fecal incontinence. Therefore, one of the major challenges in the management has been to address this problem.

The embryological basis of the pathology has been extensively reviewed and has helped in the breakthroughs in the management of the disease.[8] The classification of this disease is of paramount importance in order to properly group the malformations with a view to improve its management. [9,10] The earlier classifications such as Wingspread classification and the international classification did not fulfil a therapeutic objective. Pena's classification of the disease condition yielded appropriate therapeutic decisions and was conference on anorectal malformation held in Krickenbeck, Germany, new terminologies such as H-type malformations, rectal pouch and others have been introduced in the nomenclature. [6,11]

This report is intended to establish the trend and experience in the management of anorectal malformation in a major tertiary center in India.

## Materials And Methods

This is a retrospective and prospective review of medical records, operation registers and operation notes of patients managed for anorectal malformation in department of pediatrics surgery from June 2021 to June 2023 at major tertiary health care centre in India. Demographic data, type of anomaly, mode of presentation, evaluation, treatment and outcome of treatment were obtained. Total 590 patients' data recorded. Due to lack of reliable follow-up records, late complications were based on patients whose complications required a procedure under general anesthetic and operative records were used for this.

Data obtained were analysed using SPSS version 11.0. The  $\chi^2$  test was used to test for level of statistical significance. Level of statistical significance was set at 0.05.

## Results

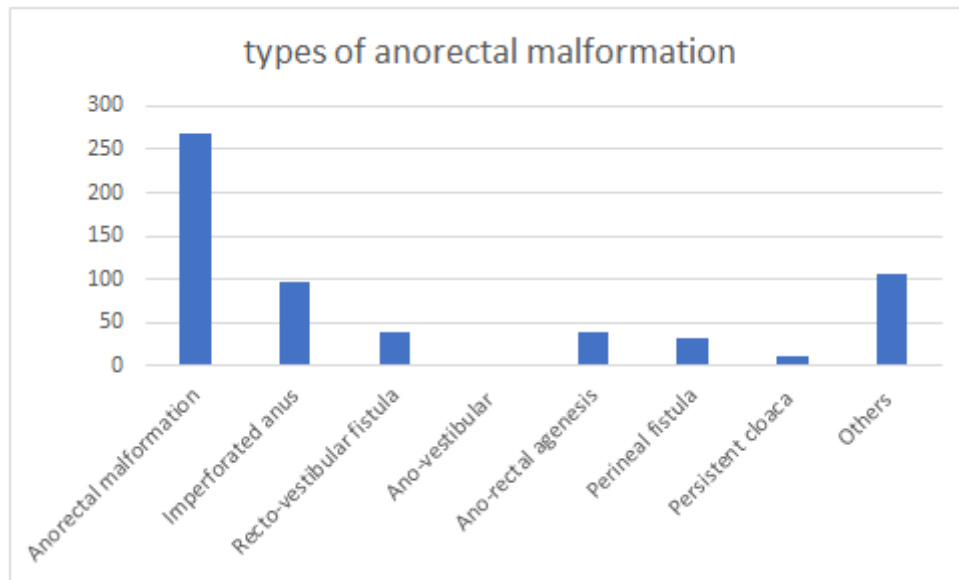
- There were a total 590 patients (376 boys and 214 girls).
- The median age at first surgery was 8 days (range 1 day–9 years).
- There were 358 emergency operations in and 232 elective operations were done.

Table no -1

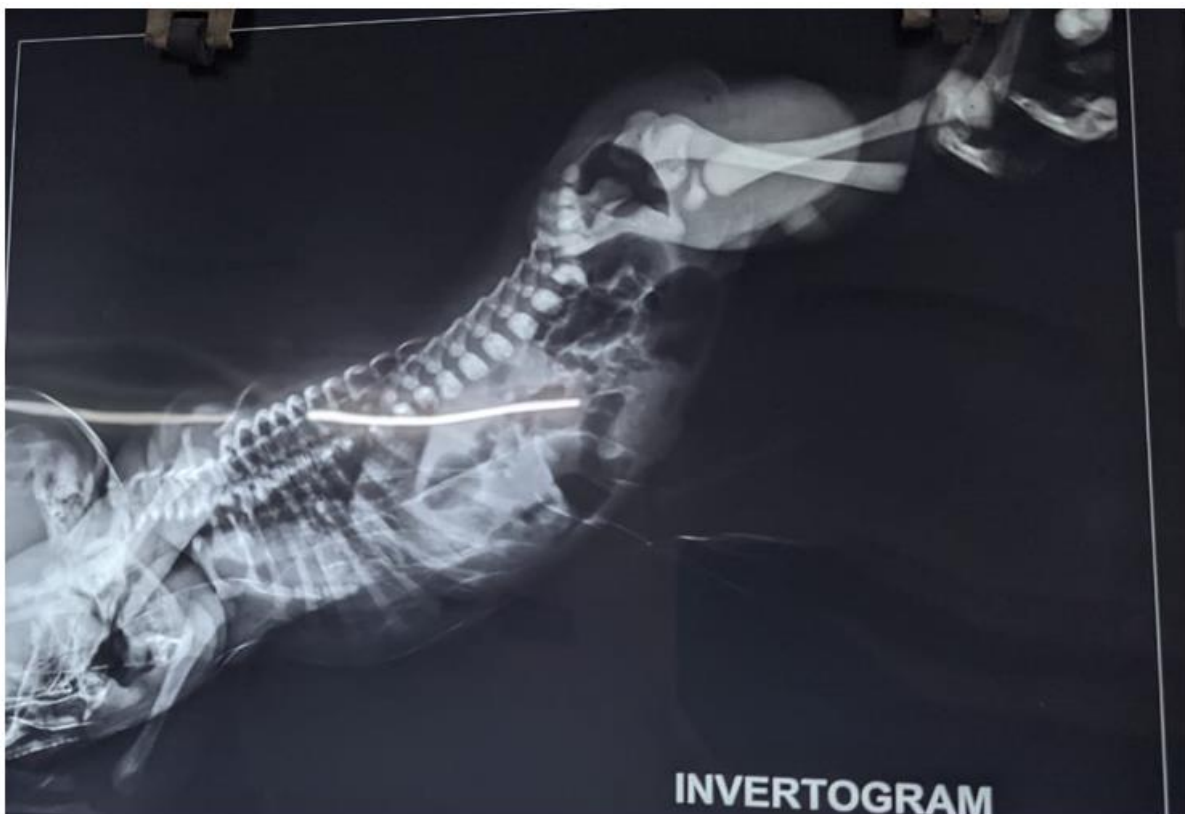Types	Numbers	Percentages
Anorectal malformation	268	45.4
Imperforated anus	96	16.2
Recto-vestibular fistula	38	6.4
Ano-vestibular	2	0.33
Ano-rectal agenesis	38	6.44
Perineal fistula	32	5.4
Persistent cloaca	10	1.69

Others	106	17.96
Total	590	100

Graph no - 1



- The main investigations for evaluation were a lateral cross table X-ray, abdominal ultrasonography, sacral X-ray, echocardiography and a distal cologram.
- total 330 patients requiring colostomy had a transverse loop colostomy. 14 patients with recto-vestibular fistula were given a colostomy before the definitive surgery, while 28 patients with recto-vestibular fistula were managed without a colostomy.



## Invertogram of intermediate ARM

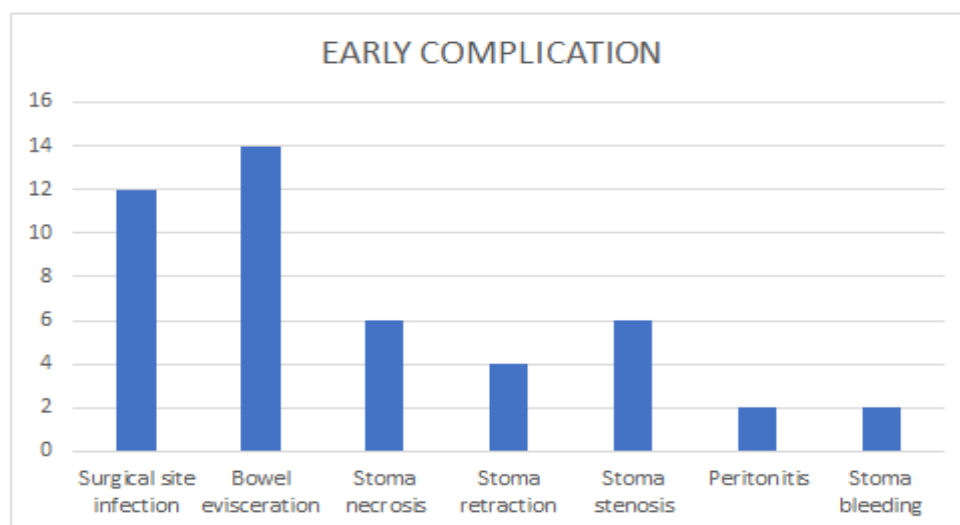
The definitive surgery done in 70 [30.14%] were cutback anoplasty, sacro-abdomino-perineal pull through 12 [5.17%], posterior sagittal ano-rectoplasty [PSARP] 104 [44.8%], anal dilatation 34 (14.6%), cruciate incision 8 (3.4%) and posterior sagittal ano-recto-vagino-urethroplasty (PSARVUP) 4 (1.72%) were done.

Operation	Numbers	Percentages
Cutback anoplasty	70	30.14
Sacro-abdomino-perineal Pull through	12	5.17
PSARP	104	44.8
PSARVUP	4	1.72
Anal dilatation	34	14.6
Cruciate incision	8	3.4
Total	232	100

-Early complications were colostomy related. The early complication rate was 14 % (46 of 330). Most common complications are bowel evisceration 30.4%, surgical site infection 26%, stoma necrosis 13%, stoma stenosis 13% and stoma retraction 8.69% were found.

## Early complications

Complications	Numbers	Percentages
Surgical site infection	12	26
Bowel evisceration	14	30.4
Stoma necrosis	6	13
Stoma retraction	4	8.69
Stoma stenosis	6	13
Peritonitis	2	4.3
Stoma bleeding	2	4.3
Total	46	100



- late complications following definitive treatment were: faecal incontinence 5 (4.3%), anal stenosis 70 (60.34%), rectal retraction 18 (15.5%), mucosal prolapse 20 (17.24%) and faecal soilage 3 (2.58%).

## Late Complications

Complications	Numbers	Percentages
Fecal incontinence	5	4.3
Fecal soilage	3	2.58
Anal stenosis	70	60.34
Rectal retraction	18	15.5
Mucosal prolapse	20	17.24
Total	116	100

- cause of death were 18 [ 3%] in which main causes are- anaesthetic deaths 2 (11.1%), overwhelming sepsis 4 (22.2%), dys-electrolytaemia 4 (22.2%) and nonspecific 8 (44.4%).

## Cause of death

Cause	Number	Percentage
Anaesthesia	2	11.1
Sepsis	4	22.2
Dys-electrolytaemia	4	22.2
Non-specific	8	44.4
Total	18	100

## Discussion

A retrospective and prospective analysis of 590 patients with anorectal malformations managed from June 2021 to June 2023 was carried out. Demographic data, type of anomaly, mode of presentation, evaluation, treatment and outcome of treatment were obtained. Total 590 patients' data recorded.

There were a total 590 patients (376 boys and 214 girls). The median age at first surgery was 8 days (range 1 day–9 years). There were 358 emergency operations in and 232 elective operations were done.

The main investigations for evaluation were a lateral cross table X-ray, abdominal ultrasonography, sacral X-ray, echocardiography and a distal cologram.

In our centre, the terminology of imperforate anus which was commonly used during the first decade, was replaced by anorectal malformation in the second decade.

Most of the patients presented as newborns to the emergency department. This is because anorectal malformation commonly presents with intestinal obstruction which is an emergency, patients frequently presented late with marked abdominal distension.

The lateral invertogram, which was a modality of investigation, was replaced by the lateral cross table X-ray. This lateral invertogram could be associated with aspiration pneumonitis or cerebral congestion when performing the procedure. The introduction of the lateral cross table X-ray was to avoid this risk.

Distal colostogram, abdominal ultrasound scan, as well as echocardiography were introduced. The distal colostogram helps to outline the nature of recto-urinary fistula as well as the level of blind rectal pouch, which are critical to the success of PSARP. The echocardiography and abdominal ultrasound scan are important in isolating associated cardiac and renal anomalies. These anomalies, when present, could influence the outcome of this condition adversely. Both abdominal ultrasound scan and echocardiography were not used because they were not readily available in our centre at that time.

Total 330 patients requiring colostomy had a transverse loop colostomy. 14 patients with recto-vestibular fistula were given a colostomy before the definitive surgery, while 28 patients with recto-vestibular fistula were managed without a colostomy.

-The definitive surgery done in 70 [30.14%] were cutback anoplasty, sacro-abdomino-perineal pull through 12 [5.17%], posterior sagittal ano-rectoplasty [PSARP] 104 [44.8%], anal dilatation 34 (14.6%), cruciate incision 8 (3.4%) and posterior sagittal ano-recto-vagino-urethroplasty (PSARVUP) 4 (1.72%) were done.

Another changing trend was in the management of anorectal malformation with recto-vestibular fistula. Some patients with this condition were managed without a preliminary colostomy, with good outcome. It was noted that proper bowel preparation before definitive surgery was adequate for those who had definitive surgery without a colostomy. One stage treatment of vestibular fistula has also been advocated by others. [13,14,15] In terms of early complications following initial treatment, colostomy-related complication rates were high. However, poor follow up makes it difficult to obtain a clear picture of late complication rates following definitive treatment.

Early complications were colostomy related. The early complication rate was 14 % (46 of 330). Most common complications are bowel evisceration 30.4%, surgical site infection 26%, stoma necrosis 13%, stoma stenosis 13% and stoma retraction 8.69% were found.

In group A, late complications following definitive treatment were: faecal incontinence 5 (4.3%), anal stenosis 70 (60.34%), rectal retraction 18 (15.5%), mucosal prolapse 20 (17.24%) and faecal soilage 3 (2.58%).

- cause of death were 18 [ 3%] in which main causes are- an aesthetic death 2 (11.1%), overwhelming sepsis 4 (22.2%), dys-electrolytaemia 4 (22.2%) and nonspecific 8 (44.4%).

Although anal stenosis occurred and the patients responded well to outpatient dilatation. This may be largely because there was a well-planned dilatation schedule after PSARP. Mucosal prolapse was also noticed following PSARP, as in another report.[16] Those with major mucosal prolapse had mucosal excision and repair to address the prolapse. Two patients developed faecal soilage after PSARP, due to lack of toilet training. The faecal soilage, however, abated after proper toilet training.

## Conclusion

Anorectal malformation remains a common defect in pediatric surgical practice. There has been worldwide evolution in the management of this condition There has been a significant change in the management of anorectal malformation with improved outcome in our center. This has been due to better understanding of the pathological condition and refinements in the surgical treatment.

## References

1. Stephens FD, Smith ED. Anorectal malformation in children. Chicago: Year book medical publishers; 1971.
2. Soranus E. In: Temkin O, translators. Soranus' gynecology book11. On the care of the newborn. Baltimore: John Hopkins University press; 1956.
3. Amussat JZ. Histoire d'une operation d'anus artificial, pratique avec success par un nouveau procede, Gaz med Paris 1835;3:753-8.
4. Stephens FD, Smith ED. Classification, identification and assessment of treatment of anorectal anomalies. *Pediatr Surg Int* 1986;1:200-5.
5. Pena A, Hong A. Advances in the management of anorectal malformation. *Am J Surg* 2000;108:370-6.
6. Holschneider A, Hutson J, Peña A, Beket E, Chatterjee S, Coran A, et al. Preliminary report on the international conference for development of standards for the treatment of anorectal anomalies. *J Pediatr Surg* 2005;40:1521-6.
7. Holschneider AM, Jesch NK, Stragholz E, Pfrommer W. Surgical methods for anorectal malformation from Rehbein to Pena: Critical assessment of score systems and proposal for a new classification. *Eur J Pediatr Surg* 2002;12:73-82
8. De Vries PA, Friedlana GW. The staged sequential development of the anus and rectum in human embryos and foetuses. *J Pediatr Surg* 1974;9:755-69.
9. Lui G, Yuan J, Geng J, Wang C. Treatment of high and intermediate anorectal malformation: One stage or 3 stages. *J Pediatr Surg* 2004;39:1466-71.
10. Levitt MA, Pena A. Anorectal malformation. *Orphanet J Rare Dis* 2007;2:33.
11. Rintala RJ. In anorectal malformation: Anything new? *J Pediatr Gastroenterol Nutr* 2009;48:s79-82.
12. Uba AF, Chirdan LB, Ardill W, Edino ST. Anorectal anomalies: A review of 82 cases seen at JUTH, Nigeria. *Niger Postgrad Med J* 2006;13:61-5.
13. Levitt MA, Pena A. Outcomes from correction of anorectal malformation. *Curr Opin Pediatr* 2005;17:394-401.

14. Adeniran JO. One stage correction of imperforate anus and rectovestibular fistula in girls: Preliminary results. *J Pediatr Surg* 2002;36:16-9.
15. Gangopadhyay AN, Gopal SC, Sharma S, Gupta DK, Sharma SP, Mohan TV. Management of anorectal malformation in Varanasi India: A long term review single and 3 staged procedures. *Pediatr Surg Int* 2006;22:169-72.
16. Belyon A, Levitt M, Shoshany G, et al. Rectal prolapse following posterior sagittal anorectoplasty for anorectal malformation. *J Ped Surg* 2005;1:192-6.
17. Pena A. Current management of anorectal anomalies. *Surg Clin North Am* 1992;72:1393-416.
18. Snyder CL, Jain VN, Saltzman DA, Strate RG, Perry JF Jr, Leonard AS. Blunt trauma in adults and children: A comparative analysis. *J Trauma* 1990;30:1239-45.
19. Eppich WJ, Zonfrillo MR. Emergency department evaluation and management of blunt abdominal trauma in children. *Curr Opin Pediatr* 2007;19:265-9.
20. Mendelson KG, Fallat ME. Pediatric injuries: Prevention to resolution. *Surg Clin North Am* 2007;87:207-28, viii. 4.
21. Lynch T, Kilgar J, Al Shibli A. Pediatric abdominal trauma. *Curr Pediatr Rev* 2018;14:59-63.
22. Wegner S, Colletti JE, Van Wie D. Pediatric blunt abdominal trauma. *Pediatr Clin North Am* 2006;53:243-56. 6. Miele V, Piccolo CL, Trinci M, Galluzzo M, Ianniello S, Brunese L. Diagnostic imaging of blunt abdominal trauma in pediatric patients. *Radiol Med* 2016;121:409-30.