

Surgical outcomes of vertebral body haemangioma with compressive symptoms -An Institutional experience

Niraj Kanaujia¹ Brajesh Kumar² Om Prakash Gupta³ Samrendra Kumar Singh⁴ Brajesh Kumar⁵

¹Associate Professor, Department of Neurosurgery, I.G.I.M.S., Patna, Bihar, India

²M.Ch. Senior Resident, Department of Neurosurgery, I.G.I.M.S., Patna, Bihar, India

³Additional Professor, Department of Neurosurgery, I.G.I.M.S., Patna, Bihar, India

⁴Additional Professor and H.O.D., Department of Neurosurgery, I.G.I.M.S., Patna, Bihar, India

⁵Associate Professor, Department of Neurosurgery, I.G.I.M.S., Patna, Bihar, India

Abstract

Background: Vertebral body (VH) hemangiomas are mostly asymptomatic, symptomatic one are difficult to manage and which treatment modality is ideal is still controversial. We would like to present our institutional experience in managing aggressive VH by surgical decompression and use of intraoperative alcohol ablation.

Objective: To know the role of intra-operative intra-lesional Ethanol injection, surgical decompression and stabilization of affected segment using Titanium Polyaxial screw and rods.

Methods: A Prospective longitudinal study done at IGIMS Patna in Symptomatic VH with compressive myelopathy.

Operative plan - Bilateral Transpedicular Intralesional absolute alcohol (<1% hydrated ethyl alcohol) injection, laminectomy decompression and stabilisation of affected segment using polyaxial Titanium pedicle screws and rod.

Results: In this study there were 19 patients in which 10 were females and 9 were males presented with back pain, myelopathy and sphincter dysfunction, having Pre-operative American Spinal Injury Association (ASIA) scores: A (9), B (5), C (3), D (2) and E (0). Mean surgical time was 120+30minutes, Mean blood loss- was 250+50 cc and mean amount of absolute alcohol used was 6+5 ml, Post op all patients improved on follow up with Follow-up ASIA scores were E (9), D (5), B (3) & C (2).

Conclusions: The use of intraoperative ethanol as an embolizing agent, laminectomy decompression and stabilization using screw and rod for symptomatic VH seems to be ideal treatment modality in resource poor Country like India.

Keywords: Vertebral Hemangioma, compressive Myelopathy, Absolute alcohol.

Introduction

Vertebral haemangiomas (VH) are one of the most common benign lesions of vertebra, Mostly they are asymptomatic but are very difficult to manage when they are symptomatic. (0.9-1.2% of cases)¹ The incidence of VH is About 10% in normal population¹. Most common location is dorsal spine and are more commonly seen in female. Single vertebral level involvement is seen in most of the patient, two vertebral involvement is rare and involvement of more than two levels is very rare²

There is various treatment modality which have been suggested in literature like 1) Embolization followed by complete vertebrectomy 2) Injection of various "cement" like material and 3) Radiotherapy. Although complete vertebrectomy would excise the tumour completely, but it is associated with huge blood loss and thus high morbidity and mortality. Injection of various embolizing agent and 'cement' like material reduce the vascularity only temporarily but there is always risk of recurrence. Ethanol embolization through a per-cutaneous route was shown to be effective but was associated with a high incidence of Pathological fractures.

To counteract these shortcomings some previous study had shown the safety, efficacy and feasibility of intra-operative ethanol embolization followed by short segment fixation using screw and rod.

Materials and Methods:

Patient selection criteria-

The Patient coming to our institute with symptoms of cord compression and myelopathic features, underwent a detailed clinical examination, imaging (plain roentgenogram, CT scans and MRI with contrast) and those who are suggestive of VH were taken in study group.

Exclusion Criteria-

Patients with pathological fractures, deformity, and other immunosuppressive conditions.

Treatment Plan—

All Patients who met inclusion criteria were sent for PAC for surgical fitness and after clearance from them they were operated by single surgeon using same Technique (Bilateral Transpedicular Intralesional absolute alcohol (<1% hydrated ethyl alcohol) injection, followed by laminectomy decompression and fixation using pedicle screws and rods.)

Surgical steps –

Under GA in prone position



Localisation of appropriate level using C Arm



Midline incision centred over spinous process were made and exposure done (one level above and below the pathological vertebral level).



Once the VH affected body was identified under fluoroscopy, pedicle screws were placed (one level above and below) into the adjacent healthy vertebrae.



After this, (14-16 gauge) Jamshidi needles were introduced into the pedicles of the affected body under C Arm guidance.



Following this, absolute ethanol (<1% hydrated) was injected using syringes attached to both the needles.



After injection of 2-3 cc on both sides, the syringe was removed.



We wait for 2-3 minutes to allow the complete action of ethanol. Then, Needle was repositioned in different areas of the vertebral body to allow homogenous embolization.



While withdrawing the needle, ethanol was injected if the embolization was not adequate.



The whole procedure was performed under operating microscope and any leakage was identified easily. For any retrograde leak seen the operating field was irrigated with normal saline along with simultaneous suction.



Laminectomy and decompression of the hemangiomas tissue was done through posterior approach. This procedure was almost bloodless due to embolization by alcohol.

Data pertaining to surgery including the operating time, amount of ethanol injected, blood loss, any significant intra operative and post op events were noted.

Soft hemangiomas tissue excised were sent for Histopathological examination for confirmation of diagnosis. Post Op, they were kept in the intensive care unit and then shifted to the ward once patient vitals and general condition were good on next day.

In the ward vitals and neurological status were monitored. Any postoperative complication were noted. Following discharge, the patients were followed up with MRI and CT scans at every 6 months. Functional outcomes were measured using ASIA impairment scale.

ASIA Impairment Scale		
A	Complete	No motor, no sensory, no sacral sparing
B	Incomplete	No motor, sensory only
C	Incomplete	50% of muscles LESS than grade 3 (can't raise arms or legs off bed)
D	Incomplete	50% of muscles MORE than grade 3 (can raise arms or legs off bed)
E	Normal	Motor and sensory function are normal

Results: The clinical features and the surgical details have been summarized below in following table

Table no 1

S.N	AGE/SEX	SYMPTOMS	ASIA SCORE (PRE OP)	LEVEL	SOFT TISSUE COMPRESSION	SURGERY	POST OP (ASIA SCORE)	COMPLICATION
1.	62/F	LBA, Paraplegic	A	D4	YES	Posterior decompression and fixation	E	None
2.	55/M	LBA, Paraplegic	A	D6	YES	do	D	do
3.	48/M	Mid and LBA, Paraplegic	A	D3	YES	do	B	do
4.	48/M	Mid and LBA	D	D7	YES	do	E	do
5.	59/F	LBA	B	D9	YES	do	E	do
6.	49/F	LBA	B	D11	YES	do	E	do
7.	42/M	LBA, Paraplegic, Sphincter dysfunction	B	D3	YES	do	C	do
8.	49/F	LBA, Paraplegic	A	D6	YES	do	D	do
9.	63/F	Mid and LBA	C	D5	YES	do	E	do
10.	62/F	LBA, Paraplegic	A	D4	YES	do	C	None
11.	55/M	LBA, Paraplegic	A	D6	YES	do	B	do
12.	48/M	Mid and LBA, Paraplegic	A	D3	YES	do	E	do
13.	48/M	Mid and LBA	D	D7	YES	do	E	do
14.	59/F	LBA	B	D9	YES	do	E	do
15.	49/F	LBA	B	D11	YES	do	D	do
16.	42/M	LBA, Paraplegic, Sphincter dysfunction	A	D3	YES	do	B	do
17.	49/F	LBA, Paraplegic	A	D6	YES	do	E	do
18.	63/M	Mid and LBA	C	D5, D6	YES	do	D	do
19.	62/F	LBA, Paraparesis	C	D4	YES	do	D	do

Total number of patients included in the study was 19 (range: 30-64 years, 10 females 9 males). Clinical features of the study population was, Features of Myelopathy seen in all (9 were paraplegic), sphincter involvement was present in two, and mid back/ lower pain was present on eighteen patients.

Pre-operative American Spinal Injury Association (ASIA) scores were as follows- Grade A (9), B (5), C (3), D (2) and E (0).

Lesion - Single vertebral involvement was present in eighteen patients and one had multiple vertebral level involvement.

Mean surgical time was- 120 ± 30 minutes,

Mean blood loss was 250 ± 50 cc.

Mean amount of absolute alcohol used was 6 ± 5 ml

Post op all patients improved at a follow up of 6 months

Follow-up ASIA scores were as follows- E (9), D (5), B (3) & C (2).

Case illustration

A 55-year-old male presented with pain in both lower limbs, right more than left, for past 5 months. He also had associated back pain and progressive weakness of both limbs (right > left) for 4 months. He also had bladder and bowel dysfunction. On clinical examination, power in lower limb was grade 2/5. MRI showed lesion arising from posterior part of body of D6, extending into epidural space causing canal stenosis. It was hyperintense on T2, iso-to-hyperintense on T1 and showed homogeneous contrast enhancement [Figure 1A].

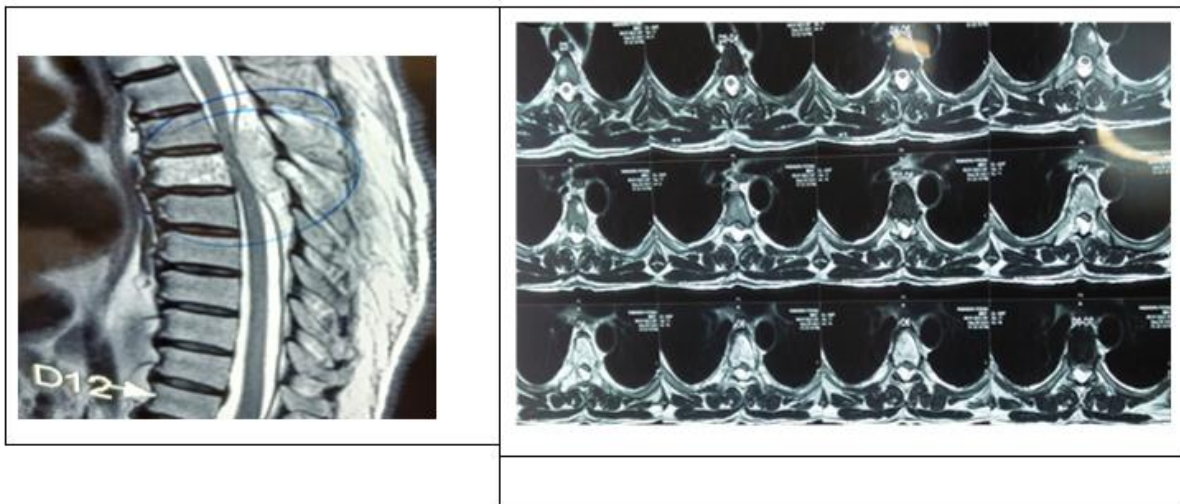


Figure 1: Case 1. (A) Sagittal and axial T2 hyper intense extradural lesion from posterior D6 body, extending into epidural space causing severe compression

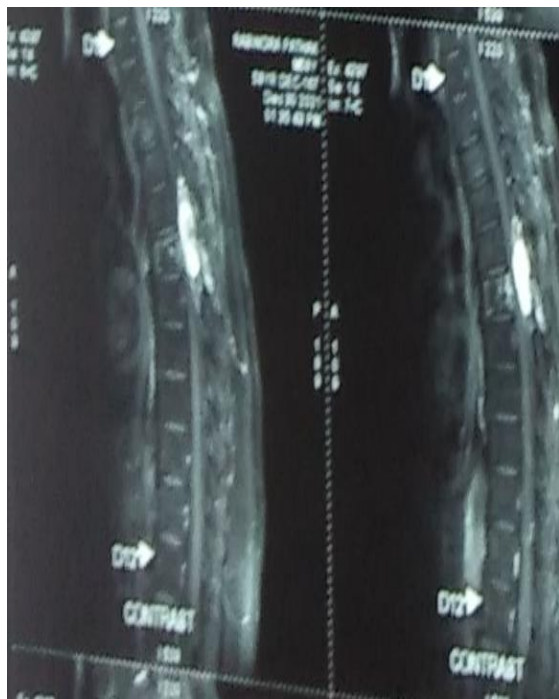

Fig 2. showing contrast enhancement

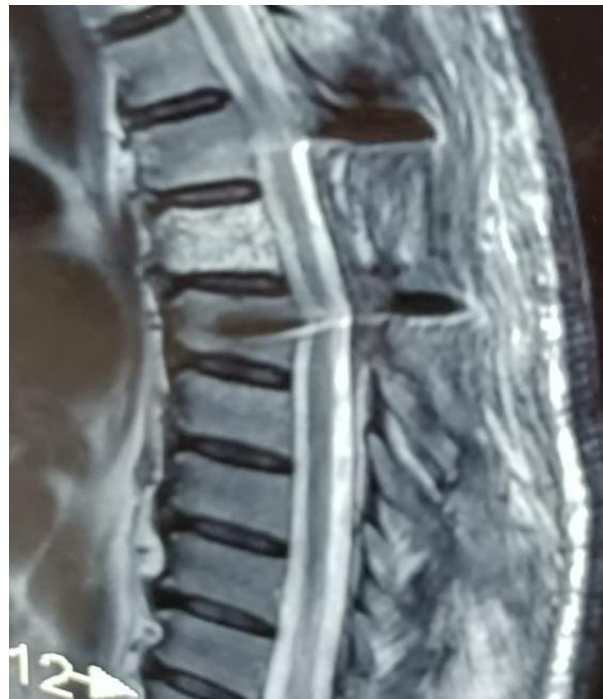

Fig 3 showing post op decompression

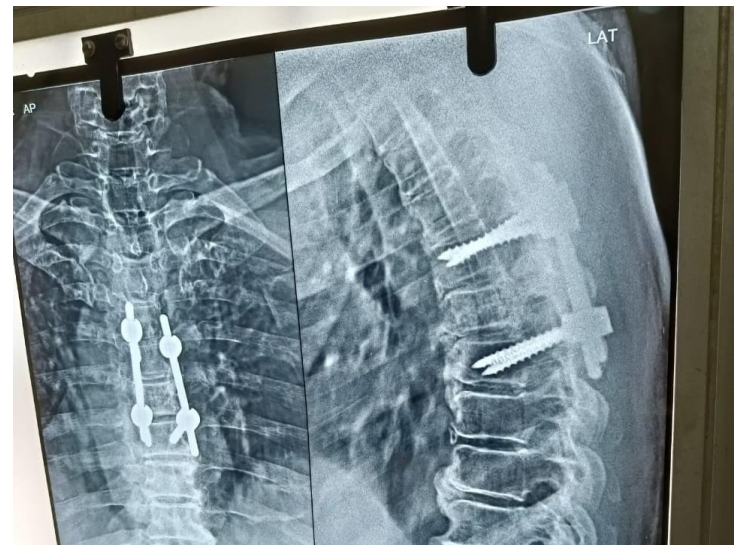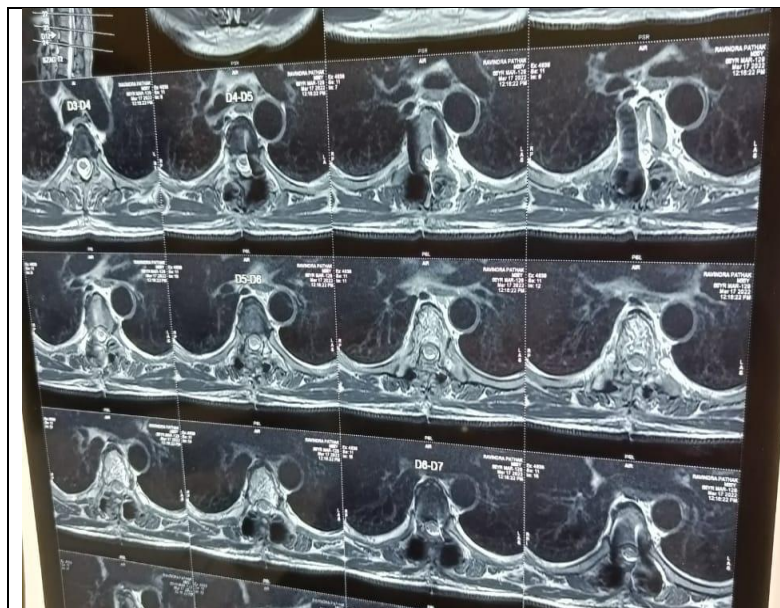
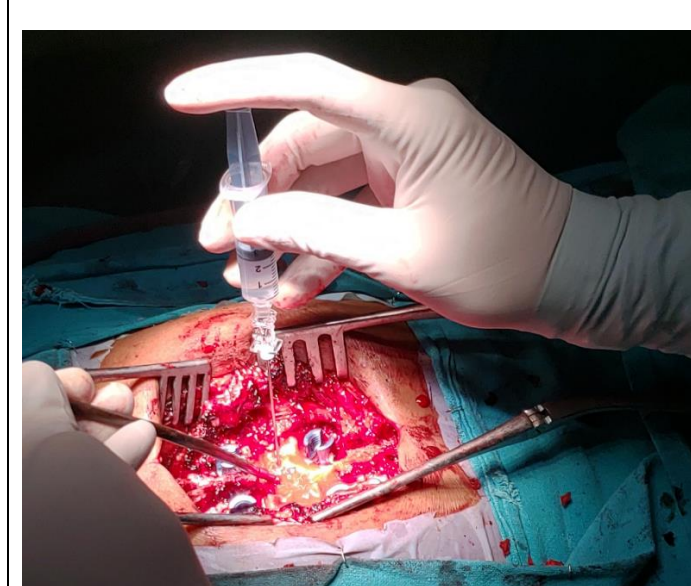


Fig 5 showing pedicle screw in situ

Fig 6 showing intralésional instillation of absolute alcohol



Following PAC, the patient was taken up for surgery; D6 laminectomy, gross total resection of tumour, and instrumented fusion was done. Intra-operative blood loss was 300 ml. Diagnosis was confirmed by histopathological examination. Postoperative MRI done showed adequate decompression. Physical therapy and rehabilitation were started. At the final follow-up, the patient had power of grade 5/5 in both lower limbs and no associated back or leg pain and was able to walk without any difficulty.

Discussion:

Virchow (1863) first reported VHs, but neurological symptoms associated with VH were first described by Gerhardt (1895). Vertebral haemangiomas are mostly asymptomatic and sometimes found incidentally on plain radiographs and on magnetic resonance images.³ They have varied presentation that depends upon location of lesion, the degree of cord or nerve root compression. On rare occasion they may enlarge and may present with features of compressive myelopathy or pathological fracture.⁴

Clinical feature-Back pain is most commonly seen symptoms and is seen in up to 54 % of cases with symptomatic VH.⁵ The maximum number of cases in the present series were located in dorsal region, which is in consistent with the published literature.

Pathology - Vertebral haemangioma are usually of dysembryogenetic origin or a hamartomatous lesion. There are three types cavernous, capillary, or a mixed. Arteriovenous shunting is rare, and these have only low-flow channels.

Aggressive variety of VHs produces symptom through on by the following mechanism-1) spontaneous epidural haemorrhage producing mass effect 2) pathological fracture causing neurological compromise and 3) expansile lesion stretching the periosteum or spinal canal stenosis.⁶

Diagnosis-

On Plain X Ray Classical finding of VH is “corduroy sign,” and CT (Axial) scan is “polka dots” appearance. Computed tomography best defines bony erosions and pathological fracture.

MRI with contrast is gold standard, with hyper intense T1 (due to high fat content) and T2 (greater than T1 due to high water content) signal and classical post-contrast enhancement (due to high vascularity) and intra-osseous signal voids.

It should be differentiated from metastasis in which there is low signal on T1 and high on T2.

MRI is helpful in assessing soft tissue involvement, spinal canal extension, and compression of cord and nerve root (features of aggressive VH). Spinal angiography has both diagnostic and therapeutic value. It delineates the vascular supply of spinal cord, haemangioma and also helps in therapeutic embolization. Non compressive vs compressive lesion may be differentiated with the help of Image finding on CT/MRI and thus helpful in surgical intervention.

Despite extensive knowledge about aggressive VH, controversy still exist regarding the optimal treatment plan of VH. Numerous treatment options have been tried in past with varying degrees of success and complications. There is still no universally accepted protocol/management strategy for aggressive VHs. VH usually require Multimodal treatment therapy along with surgery .Important factors that help in deciding the adjuvant therapy are--Patient symptoms, Level of lesion , surgeon’s preference, and response to treatment and finally the Access to interventional radiology services and costs involved. Relevant literature regarding treatment of VH are as follows-

Alcohol ablation--

Ethanol was first used to produce angio-infarction of kidneys for uncontrolled hypertension. In 1994, Heiss et al first reported vertebral hemangioma treatment by percutaneous CT-guided injection of absolute alcohol. It causes intrarelesional thrombosis and destruction of the heamangiomatic endothelium .It causes devascularisation, shrinkage and subsequent sclerosis of hemangioma which decompresses the cord and nerve roots. According to Goyal et al there is success rate of 86% with a percutaneous procedure with alcohol ablation in VH.

A study done by Chandra *et al.*⁷for symptomatic VH was treated by similar methods used in present study, They reported excellent clinical improvement. Some study showed transient deterioration of neurological function in some patient as evidenced by study of Goyal *et al.* and Yadav *et al.*⁸

Major issues with ethanol use is its rapid “run off” into systemic circulation and thus producing systemic side effects and it can also leads to toxic necrosis of normal surrounding tissues when it spills over.^{9,10} VH have low flow fistulas and also no AV shunting so these side effects are generally not seen causing local retention of alcohol sclerosing action to take place.

VH ethanol embolization has the unique feature of both providing instant embolization and also ‘killing’ the tumor cells. In some cases of per-cutaneous injection of ethanol, some patients developed pathological fractures ,which depends on volume of ethanol injected (>40 ml). In such cases, once the tumor was embolized and underwent necrosis by ethanol, the residual bony lattice is unable to support the weight of the body leading to vertebral collapse , so there is need of stabilisation when we are using alcohol .

In spite of these complications, intra-operative intralesional ethanol injection still remains a highly cost-effective, easily available technique, especially in Resource poor country like India and Bihar where resources for interventional radiologists are unavailable

Surgery-

Surgery in aggressive VH, is one of the well-established treatment modality. Majority of them have extra osseous tumor tissue and compression on neural structures from outside causing neurological dysfunction. Today surgical intervention is very safe option with the use of adjuvant therapy like embolization, alcohol ablation, and vertebroplasty^{11,12}. Today the surgical morbidity and mortality have come down making them a very safe option.

The current accepted strategies for surgical management of VH include vertebrectomy¹⁸ (usually with embolization), injection of 'cement' like substances using either vertebroplasty^{13,14} or lymphoblastic and radiotherapy

Initially en bloc surgical resection was used mainly to prevent recurrence, but it was associated high morbidity and even mortality in few cases. Currently, the main aim of surgery in aggressive VH is decompression. Surgical options range from laminectomy, debulking, to gross total resection.

According to studies by Fox and Onofrio, Surgical modality was subtotal resection and they reported recurrence of tumor in those patients who did not given any adjuvant radiotherapy.

According to Acosta *et al*¹⁵ transarterial embolization with laminectomy is found to be very safe and effective.

A very similar findings was published by Goldstein *et al.* and Chandra *et al.*, in which all patients underwent decompression of neural structures only through posterior approach.

Surgical intervention has been associated with significant morbidity, the main issue being excessive intra-operative blood loss and post-operative hematoma. Hence, these patients should be thoroughly evaluated for any bleeding tendency and adequately optimized pre-operatively. The various adjuvant modality help to an extent to deal with excessive blood loss. Other measures to deal with intra-operative blood loss are use of intra-operative tranexamic acid infusion, judicious use of haemostatic agents such as thrombin products, fibrin sealants, oxidized cellulose, gelatine foams, and collagen sponges. Maintaining optimal intra-operative blood pressure plays an important role to reduce blood loss. Average blood loss in our patients was around 300 ml. Good haemostasis and closure of surgical site and use of negative suction drain help to reduce risk of post-operative hematoma.

Endovascular Embolization

Uncontrolled haemorrhage is one of dreaded complication of VH. for which Transarterial embolization is an universally accepted, safe, and effective procedure. Earlier studies that have shown good results of this techniques are done by Gross *et al.* and Hekster and Endtz *Raco et al.* and by Smith *et al.*

A study done by Prabhuraj *et al.*²⁹ (2019) recommend the use of preoperative transarterial embolization.

Radiotherapy

For the treatment of VH low dose of radiation is used (30-49 Gy). They were used in cases where there was incomplete tumor removal and in cases of VH associated with pain. Nowadays the use of post op radiotherapy is obsolete due to advancement in adjuvant therapy. Use of radiotherapy in aggressive VH is still controversial as they cause reduction in tumor size only after a delayed time period.¹⁷ It causes radiation necrosis to neural tissues. Also it causes skin ulceration.

Conclusion

Aggressive VH is treated by surgery most of time and nowadays, a decompression surgery through posterior approach is preferred due to less morbidity with good outcomes. As there is no standard protocol regarding use of Various adjuvant therapies available in literature to be used with good clinical outcomes. Each of them has its own pros and cons.

In our limited experience, we performed laminectomy decompression through posterior approach and excision of epidural/soft tissue component causing compression and stabilisation using Titanium screw and rods. The intra-operative blood loss and tumor recurrence was taken care with use of intralesional alcohol ablation.

Conflict of interest –None

Abbreviation – VH = Vertebral haemangioma, PAC=pre-anaesthesia checkup, CT-computed Tomography, MRI=Magnetic resonance imaging

References:

1. Acciarri N, Padovani R, Giulioni M, Gaist G. Surgical treatment of spinal cavernous angiomas. *J Neurosurg Sci.* 1993;37(4):209-215.
2. Baker ND, Klein MJ, Greenspan A, Neuwirth M. Symptomatic vertebral 16 hemangiomas: a report of four cases. *Skeletal Radiol.* 1986;15(6):458-463.
3. Esparza J, Castro S, Portillo JM, Roger R. Vertebral hemangiomas: spinal angiography and preoperative embolization. *Surg Neurol.* 1978;171-173.
4. Feuerman T, Dwan PS, Young RF. Vertebrectomy for treatment of vertebral hemangioma without preoperative embolization. Case report. *J Neurosurg.* 1986;65(3):404-406.
5. Graham JJ, Yang WC. Vertebral hemangioma with compression fracture and 5 paraparesis treated with preoperative embolization and vertebral resection. *Spine (Phila Pa 1976).* 1984;9(1):97-101.
6. Tarantino R, Donnarumma P, Nigro L, Delfini R. Surgery in extensive vertebral hemangioma: case report, literature review and a new algorithm proposal. *Neurosurg 17 Rev.* 2015;38(3):585-592; discussion 592.
7. Chandra SP, Singh P, Kumar R, Agarwal D, Tandon V, Kale SS, *et al.* Long-term outcome of treatment of vertebral body hemangiomas with direct ethanol injection and short-segment stabilization. *Spine J* 2019;19:131-43
8. J 2019;19:131-43
9. Yadav N, Prabhakar H, Singh GP, Bindra A, Ali Z, Bithal PK. Acute hemodynamic instability during alcohol ablation of symptomatic vertebral hemangioma: A prospective study. *J Clin Neurosci* 2010;17:810-1.
10. 9. Guedea F, Majó J, Guardia E, Canals E, Craven-Bartle J. The role of radiation therapy in vertebral hemangiomas without neurological signs. *Int Orthop* 1994;18:77-9.
11. 10. Burton AW, Rhines LD, Mendel E. Vertebroplasty and kyphoplasty: a 26 comprehensive review. *Neurosurg Focus.* 2005;18(3):e1.
12. 11. Durov OV, Shevelev IN, Tissen TP. [Vertebroplasty in the treatment of spinal 38 diseases]. *Zh Vopr Neurokhir Im N N Burdenko.* 2004(2):21-25; discussion 26.
13. 12. Atalay B, Caner H, Yilmaz C, Altinors N. Sacral kyphoplasty for relieving pain caused by sacral hemangioma. *Spinal Cord.* 2006;44(3):196-199.
14. 13. Boschi V, Pogorelic Z, Gulan G, Perko Z, Grandic L, Radonic V. Management of 23 cement vertebroplasty in the treatment of vertebral hemangioma. *Scand J Surg.* 2011;100(2):120-124. 25
15. 14. Fuwa S, Numaguchi Y, Kobayashi N, Saida Y. Percutaneous pediculoplasty for 42 vertebral hemangioma involving the neural arch: a case report. *Cardiovasc Intervent 43 Radiol.* 2008;31(1):189-192.
16. 15. Prabhuraj AR, Mishra A, Mishra RK, Pruthi N, Saini J, Arvinda HR. Per-operative glue embolization with surgical decompression: A multimodality treatment for aggressive vertebral haemangioma. *Interv Neuroradiol* 2019;25:570-8.
17. 18. Interv Neuroradiol 2019;25:570-8.